

POSTURAL AND VENTILATORY FUNCTIONS OF INTERCOSTAL MUSCLES

B. DURON

Laboratory of Neurophysiology, Faculty of Medicine, Amiens, France

Abstract. During spontaneous breathing, the interchondral muscles present a pattern of activity similar to that of the diaphragm. The external intercostals and most of the internal intercostals generally show electrical discharges not related to ventilatory rhythm. Studies of the electrical responses of these muscles in experimental variations of their length show that the external and internal intercostals are readily activated by this category of reflexes while the diaphragm and the interchondrals are not. Bilateral multisegmental sections of spinal dorsal roots do not affect the respiratory activity of the diaphragm and of the interchondral muscles; on the contrary, all types of activity — spontaneous or reflex — disappear from the intercostals. Electrical stimulation of appropriate points in the bulbar pyramids in decerebrate cats can activate at the same time different intercostals and leg muscles without modifying the rhythmic inspiratory activity of the diaphragm and the interchondrals. In preparations with chronically implanted electrodes, the intercostal muscles are chiefly involved in posture. These results fit very well with our histological findings which disclose a much greater density of muscle spindles in external intercostals than in the diaphragm or in the interchondral muscles.

INTRODUCTION

Our conception of the role played by the intercostal muscles has been dominated for a long time by the anatomical concept of the "thoracic cage" starting with the original mechanical explanation of Hamberger (1748) based on geometric considerations. Thus, it has seemed logical to attribute an inspiratory function to raising the ribs and an expiratory function to lowering them. This reasoning was widely accepted and one can find in Wright (1961) "The external intercostals and the inter-cartilaginous internal intercostals raise the ribs and thereby increase the an-

tero-posterior diameter of the thorax during quiet and increased inspiration. They are powerful respiratory muscles”.

This could imply that, during a given respiratory phase, all the intercostal muscles of the same nature contract together. However, following Tokizane, Kawamata and Okizane (1952) and Campbell (1952), a number of other authors studied the role of the different intercostal muscles in ventilation by electromyographic analysis in man and other species (Jones et al. 1953, Rossier et al. 1956, Koepke et al. 1958, Ramos 1959, Delhez et al. 1959, Taylor 1960). The divergences with Hamberger's classical theoretical conception are sometimes considerable. Thus, according to Comroe et al. (1967), the external and internal intercostals should serve only to maintain the tension of the corresponding spaces, avoiding inspiratory depression of the latter or expansion on coughing.

But the thorax is from every indication involved in postural function (Magnus 1924), and the existence of postural reflexes at the level of certain intercostals has been demonstrated by Massion, Meulders and Colle (1960).

Thus, one can believe that the divergences of the results are related to the different participation of the various muscles in one or other of the two main functions (ventilation and posture). As a result of this, the interpretation of the regulatory role of the muscle spindles studied recently by Eccles, Sears and Shearly (1962), Sears (1963), Critchlow and Euler (1963), and Andersen and Sears (1970) is difficult.

Therefore, it seemed necessary for us to attempt a systematic study of the different respiratory muscles so as to define the relative importance of their postural and ventilatory roles. Electromyography seemed to be the preferred method, so we adapted this to our requirements. From a physiological point of view, animal preparations are never satisfactory. Indeed, the diffuse, little understood action of anaesthetics on the central and peripheral nervous system (Paton and Speden 1965) causes respiratory and ventilatory depressive effects (Severinghaus and Larson 1964). On the other hand, the decerebrate and spinal preparations are artificial and result in an important malequilibration of spinal excitability. Thus, we chose to make a comparative study in different experimental conditions. Finally, we tried to relate our electrophysiological findings with an anatomical study involving the relative spindle density in the various respiratory muscles.

METHODS

This study, including several series each involving at least 30 experiments, was with adult cats of either sex and weighing between 3 to 4 kg.

ANIMAL PREPARATIONS

In each case tracheostomy, isolation of both vagus nerves and carotid arteries, and catheterization of a femoral artery and vein were done. The intra-thoracic pressure variations were detected by an oesophageal balloon. For the anaesthetized preparation, we used pentobarbitone (40 or 30 mg/kg). Decerebration was performed under halothane anaesthesia by an intercollicular section. The two cerebral hemispheres were removed by suction. This allowed good haemostasis in the cranial cavity. During the decerebration the carotid arteries were clamped temporarily. Two or three hours were allowed for the complete elimination of halothane. Cervical spinal section and bilateral section of the thoracic dorsal roots were also carried out under halothane anaesthesia in the decerebrate cat.

Several reflexes (lung inflation and deflation, and passive movements of the thorax) were examined before and after bilateral vagotomy. The electrical activity of the respiratory muscles was also studied in unrestrained cats with chronically implanted electrodes.

ELECTROMYOGRAPHIC TECHNIQUE

The muscular electrical activity was recorded via bipolar electrodes (Duron and Condamin 1969) consisting of two insulated copper wires (0.1 mm diameter) on which there are two non-insulated points separated from one another by 1 to 2 mm. These two active points were 3–4 mm from a small lead piece which kept the two wire ends together. The two conducting ends on emerging from the lead were surrounded in latex in order to insulate them. The electrodes were placed in the muscular tissue using a curved or straight fine needle. A second piece of lead, holding the wires leaving the muscle, prevented any displacement of the electrodes.

The diaphragm was reached through the abdomen. After setting the electrodes the abdominal wall was closed off in three layers. At the level of the intercostal space, the electrodes were placed in the neighbourhood of the motor end-plates (Duron and Condamin 1968) in the thickness of the three types of respiratory muscle: external intercostal, internal intercostal and the intercartilaginous part of the internal intercostal or the "interchondral" muscle. To reach these muscles, it was necessary to go through the pectoralis and between the digitations of the serratus anterior. We used a median, pre-sternal, cutaneous incision which allowed us to reach on one side the intercostals and the serratus anterior and, on the other, the intact pectoral muscle.

The access to the internal intercostal required partial ablation of the corresponding external intercostal. A short incision (0.5–1 cm in length)

along the inferior rib allowed one to turn back a little slip of muscle without damaging the external intercostal nerve. The creation of a pneumothorax was carefully avoided. When all the electrodes were set, the superficial muscular plane was reconstructed and the skin sewn.

PYRAMIDAL STIMULATION

For the stimulation of the pyramidal tract, the latter was reached in the unanaesthetized, decerebrate cat with a bipolar electrode 0.4 mm in diameter inclined at an angle of 30° . This electrode entered under the posterior colliculus, crossing the trapezoid body where an acoustic evoked potential could be recorded.

The stimulated points were subsequently coagulated for histological examination. The duration of the currents was 0.1 sec. They consisted of rectangular shocks lasting 50 μ sec, 7 to 10 v in amplitude and of 300 Hz.

RECORDING

The electrical activities were amplified (using a differential amplifier, type Grass P 511) and displayed on an oscilloscope (Tektronix type RM 565) and filmed by a Grass camera. In certain experiments, we used a Polygraph, type Grass 7. The oesophageal and arterial pressures were monitored respectively by strain-gauge manometer (Statham, type P 23 BB and P 23 AC). The tidal volume was measured by a spirometer with oxygen compensation.

QUANTITATIVE AND TOPOGRAPHICAL STUDY OF INTERCOSTAL MUSCLE SPINDLES

This study was made on a muscular section which was perpendicular to the direction of the muscle fibres. The projection of the different sections on one plane allowed reconstruction of the studied muscular block. The dry weight of the tissue was determined after dehydration with alcohol and drying out with filter paper.

RESULTS

ACUTE EXPERIMENTS

In all these experiments, regardless of the type of preparation (anaesthetized or decerebrate) the animal was kept lying on its abdomen with its head fixed in an Horsley-Clarke apparatus. The body temperature was maintained at 37°C . The cat breathed spontaneously. The respiratory muscles electrical activity was therefore recorded in similar conditions in each experiment.

The spontaneous electrical activity of the intercostal muscles in the anaesthetized cat

Deep anaesthesia (Fig. 1)

In an animal deeply anaesthetized with pentobarbitone (intra-peritoneal 40 mg/kg) the maximum arterial pressure is raised to about 110 mm Hg. The minute volume of about 0.9 litres/min is in the region of the values given by Crosfill and Widdicombe (1961).

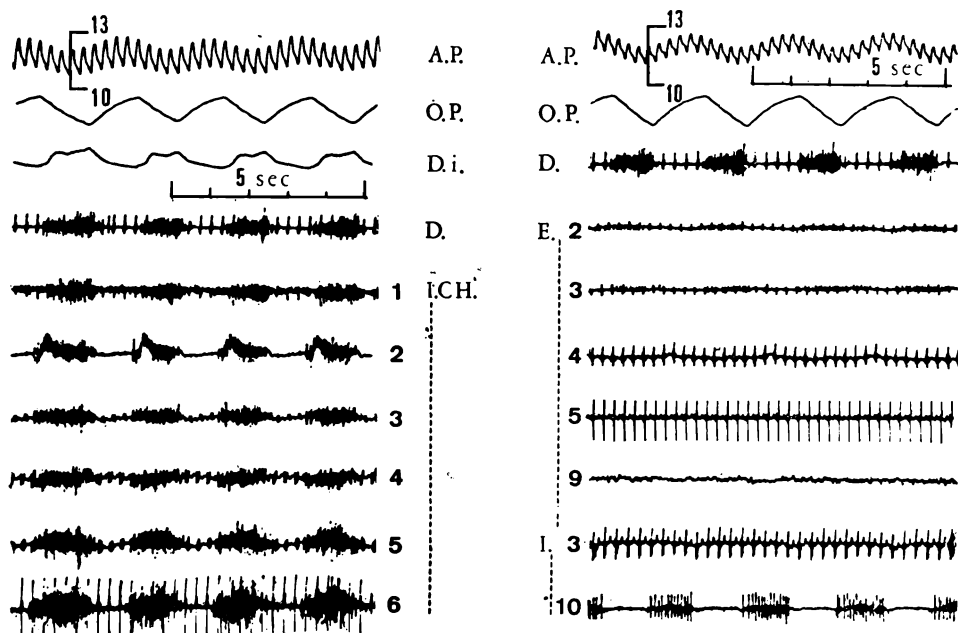


Fig. 1. Polygraphic study of the respiratory muscles during deep pentobarbitone anaesthesia. A. P., arterial pressure (cm Hg); O. P., oesophageal pressure; D. I., integrated electrical activity of the diaphragm; D., diaphragm; I. CH., interchondral; E., external intercostal; I., internal intercostal. The numbers represent the space levels.

According to Bronk and Ferguson (1943) and of Sant'Ambrogio and Widdicombe (1965), the first six interchondral muscles have a phasic activity which is strictly inspiratory, synchronous with that of the diaphragm.

The external intercostals of all the spaces are generally inactive. The electrical silence analogous to that of the limb muscles is especially marked in the five inferior spaces. In the superior spaces phasic activity may occur during inspiration.

The *internal intercostals* are also inactive except for those of the 9th and 10th spaces where a phasic expiratory activity frequently occurs.

The *triangularis sterni* and the *transversus abdominalis* also have activity during expiration. When anaesthesia is increased by repeated intravenous injections of pentobarbitone, the activity of both external and internal intercostals is no longer observed. On the other hand, a tonic activity appears both in the diaphragm and in the interchondrals. This evokes in "apneustic attack" conforming with the results of Robson, Houseley and Solis-Quiroga (1963).

Nevertheless, the 1st and 2nd interchondral activity may disappear, but that of the 3rd and 4th persists (Duron 1968*ab*).

Light anaesthesia (Fig. 2)

Light anaesthesia is obtained by an initial interperitoneal injection of 30 mg/kg of pentobarbitone. Afterwards, in order to prevent the animal

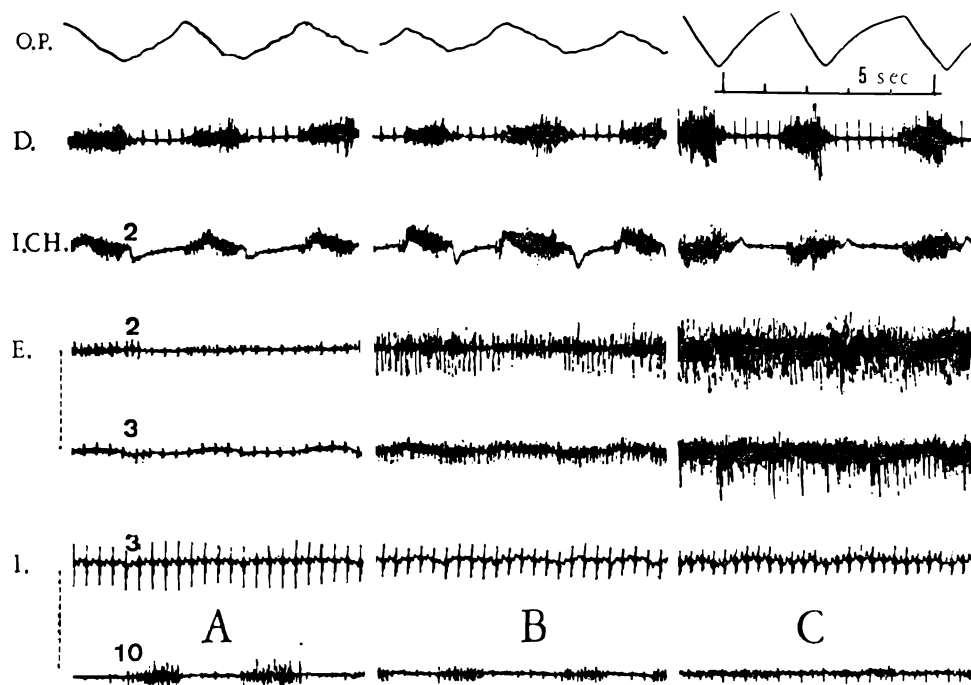


Fig. 2. Progressive dissipation of pentobarbitone anaesthesia. The successive sequences (A, B, C) show the modifications of the respiratory electrical activity when the animal awakes. Note in B in the external intercostals (E) the simultaneous presence of inspiratory and expiratory units. Since the level of anaesthesia is low (C), the external intercostals show a tonic activity. The abbreviations are as for Fig. 1.

moving, the anaesthesia may be deepened by small additional intravenous injections.

Progressive reinforcement of intercostal activity is observed as the animal awakes and as activity in the postural muscles reappears. At the intermediate stages of awakening, both inspiratory and expiratory motor unit activity may be observed (Fig. 2B) at the level of the external intercostals. As the animal becomes more alert (Fig. 2C), the external intercostals show maintained tonic activity. On the other hand, the diaphragmatic and interchondral electromyograms remain unchanged.

The effect of temperature

It is easy to evoke the shivering reflex (Richet 1893) in the lightly anaesthetized cat without producing much hypothermia. Cooling of the surrounding atmosphere to 18°C is all that is required. It was interesting to use this method to analyse in this particular situation the comportment of the intercostal muscles compared with that of the postural muscles which are readily involved in shivering (Hemingway 1963).

Thus, as we have more than once observed (Duron 1966, Duron and Caillol 1971*ab*) the characteristic muscular trembling seen in the limbs and thorax is modified by the respiratory rhythm and provides expiratory reinforcement. The respiratory muscles take part in shivering according to a certain hierarchy. The diaphragm never participates in it. The interchondrals are involved only minimally. It is the external intercostals which are most important in this activity. The latter show electrical activity of the same pattern as that of the postural muscles of the thorax and limbs which are involved in shivering. During the respiratory stimulation provoked by partial tracheal obstruction, the interchondral shivering disappears while it persists in the external intercostals despite their increased inspiratory activity.

Afterwards, probably because of the increasing hypoxia (Euler 1961), the shivering gradually disappears in both the intercostals and postural muscles. These results show the importance of such varied factors as anaesthetic level and surrounding temperature. They explain not only certain disagreements in publications concerning intercostal activity, but also underline the care which must be used in interpreting the phasic electrical activities which have a respiratory rhythm.

Spontaneous electrical activity of intercostal muscles in the unanaesthetized, decerebrate cat (Fig. 3)

Even though the decerebrate preparation is artificial, it has the advantage of avoiding anaesthesia. It forms a reference of which the main characteristic is doubtless the facilitation of the gamma system.

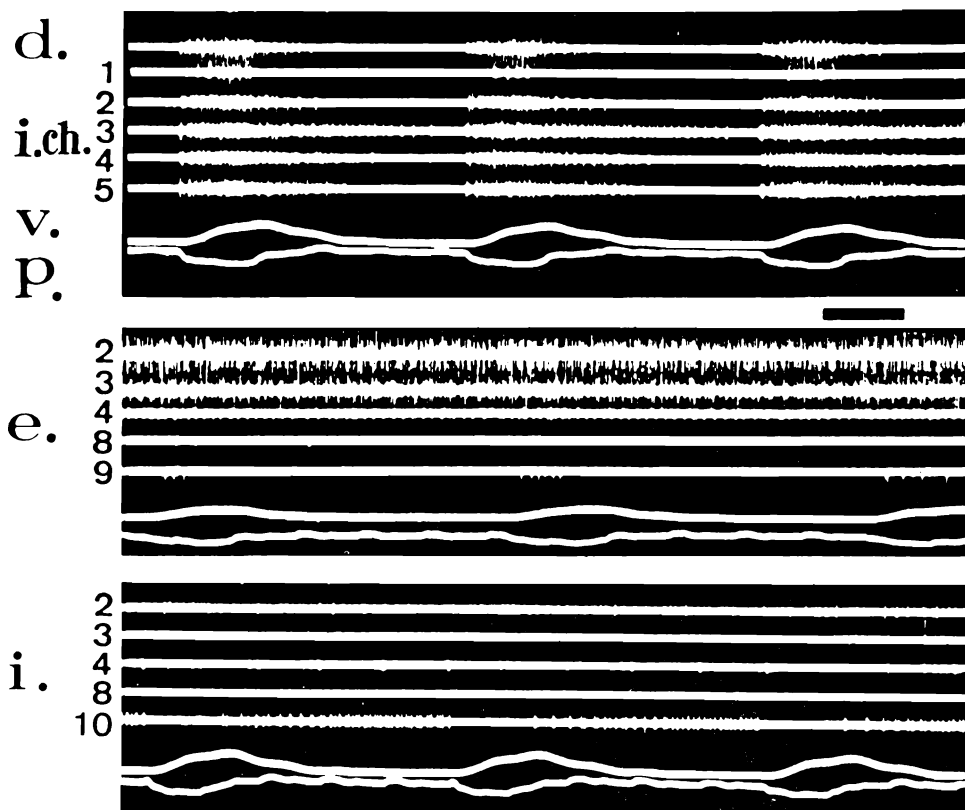


Fig. 3. Polygraphic study of the respiratory muscles in the decerebrate preparation. Note the phasic, inspiratory activity of the diaphragm (*d*) and the 1st 5 interchondrals (*i.ch.*) and the phasic expiratory activity of the 10th internal intercostal (*i.* 10). The four first external intercostals present a tonic activity (*e.* 2-4). The other muscles are inactive. A slight inspiratory activity is visible in the 2nd external intercostal in exceptional cases. *v*, volume; *p*, oesophageal pressure.

The respiratory frequency varies between 30 and 60 cycles/min. The usual value is approximately 40 cycles/min. The respiratory flow is between 1 and 1.4 litres/min. The maximal arterial blood pressure is increased to 140 mm Hg. Decerebrate rigidity was clearly present in all our experiments.

The most frequent pattern of respiratory muscle activity is shown in Fig. 3. The electrical activity of the diaphragm remains purely phasic. Some potentials may appear in the initial phase of expiration. The interchondral activity is likewise phasic. Each synchronous inspiratory discharge appears a few fractions of a second after the start of the diaphragmatic discharge.

The activation of these muscles often takes place sequentially. The 1st and 2nd space muscles are activated with a delay compared to those of the 3rd and 4th spaces. This delay tends to disappear when the respiratory rate is increased. In certain cases, a maintained tonic activity is superimposed on the inspiratory activity, but the latter is always clearly seen.

The seven superior external intercostals always show a maintained tonic activity. It is rare that a clear inspiratory modulation is observed (Duron 1966). On the contrary, below the 8th rib, the external intercostals are often inactive. They may sometimes show a tonic activity but rarely an inspiratory one. The expiratory activity of the underlying internal intercostals is most frequently picked up by electrodes at this level. In the majority of cases, partial obstruction of the trachea does not cause inspiratory activity to appear in these muscles.

The internal intercostals of the lowest four spaces shown an expiratory phasic activity. They may also be tonic or silent. The other internal intercostals are generally inactive. Sometimes, a tonic activity may be recorded from the first two intercostal spaces. The triangularis sterni and the transversus abdominalis are always expiratory.

Section of the thoracic spinal dorsal roots (Fig. 4)

In each case, we first made a decerebration and recorded the electrical activity of the various muscles after dissipation of anaesthesia. Then, we cut the dorsal roots between the 2nd cervical and 2nd lumbar seg-

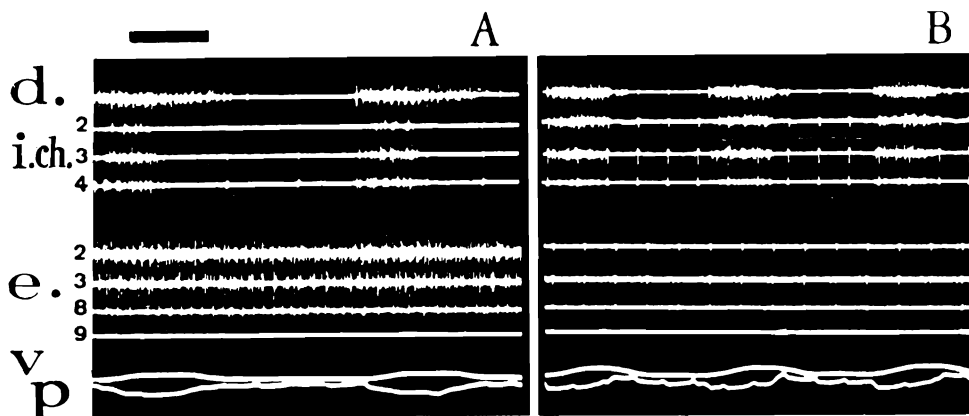


Fig. 4. The effect of dorsal root section. *A*, polygraphic recording of the electrical activity of the diaphragm, the interchondrals (i.ch. 2, 3, 4) and the external intercostals (e. 2, 3, 8, 9) in the decerebrate cat. *B* shows a recording from the same muscles after bilateral cervical and thoracic root section from C₂ to L₂.

Time scale, 1 sec.

ments on both sides using halothane anaesthesia. After arrest of anaesthesia, decerebrate rigidity progressively reappeared in the hind limbs. This recuperation of the extensor tonus constitutes a good criterion for the state of the preparation and the elimination of anaesthesia. The recording of the muscular activity is then made. The frequency of breathing tends to accelerate (Duron 1968a), but it is difficult to attribute this with conviction to the dorsal spinal root section. The activity of the diaphragm and of the interchondrals is strictly inspiratory. During the expiratory phase, a total electrical silence exists. The external and internal intercostals become entirely inactive (Fig. 4). On the other hand, spinal section at the 7th cervical level cancels interchondral activity while the external intercostals remain active.

The results allow one assimilate the tonic intercostal activity observed in the decerebrate cat as a manifestation of a gamma rigidity similar to that of the limb extensors. On the other hand, the electrical silence observed after deafferentation of the external intercostals shows the importance of the role played by the afferent influx in the activation of these muscles (Andersen and Sears 1970). The role of these afferent nerves seems to be of little importance as far as the diaphragm and the interchondrals are concerned.

Thus, the control of these two inspiratory groups of muscles seem to be different.

The influence of muscle relaxants (Fig. 5)

In order to avoid the traumatic disorganization following dorsal root section, we studied the effect in the decerebrate cat of diazepam (Valium) whose muscle relaxant action is well known. In addition this drug injected intravenously provokes a vagal reflex inhibition of respiration (Duron and Regis 1967). This inhibition arises rapidly and precedes the muscle relaxation. This allows one to dissociate the inspiratory and postural activities of the external intercostals.

In Fig. 5 the persistence of the intercostal tonic activity is seen during the apnoea due to diazepam; and secondly the phasic inspiratory activity of these muscles is visible on the electromyogram. From these results one may envisage that the external intercostals are subjected to two kinds of influence which are relatively independent. One involves the supposed mechanism which regulates posture, the other involves the descending projections from the respiratory centre.

To summarize the results obtained in these different experimental categories, one can classify the ventilatory muscles according to their electrical pattern (Table I). In this Table, an opposition between, on the

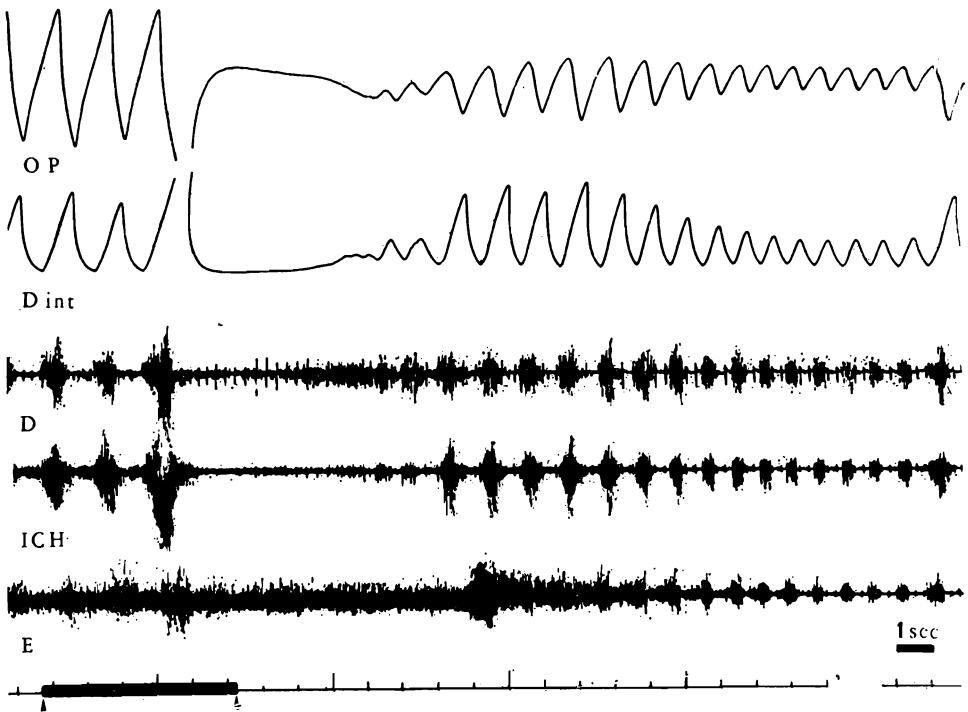


Fig. 5. The effect of diazepam on the electrical activity of the respiratory muscles. O. P., oesophageal pressure; D int., integrated electrical activity of diaphragm; ICH, interchondral; E., external intercostal muscles. The two arrows below mark the period of intravenous injection of 0.3 mg/kg of diazepam. Before and during the injection, the electrical activity of the external intercostals is both tonic and inspiratory. During reflex apnoea only the tonic activity persists in these muscles. After the drug's action, the external intercostal activity is strictly phasic and inspiratory.

TABLE I

Classification of the ventilatory muscles according to their electrical pattern

Muscle		Phasic activity		Tonic activity
		Inspiratory	Expiratory	
Diaphragm		+++		0
Interchondrals (6 superior spaces)		++		+
External intercostals	7 superior spaces	+		+++
	5 inferior spaces	(+)		+
Internal intercostals	7 superior spaces		(+)	+
	5 inferior spaces		++	(+)
Triangularis sterni			++	

one hand the diaphragm and interchondrals, and on the other hand the external intercostals, is observed. The latter although they may sometimes be involved in ventilation generally present an activity very comparable to that of the postural muscles.

Several passive natural stimulations modifying the tension of the intercostal spaces were used to extend this analytic study.

*Role of afferent nerves from thoracic segments
in the activation of respiratory muscles*

Activation of the parietal thoracic afferents was brought about by several methods in the decerebrate unanaesthetized vagotomized animal. Following Ramos (1959), Ramos and Mendoza (1959), and Sant'Ambrogio and Widdicombe (1965), we used pulmonary inflation and deflation in order to vary the tension of the various intercostal muscles. We also studied the effects of external compression of the thorax and those of passive postural movement (Duron 1968b).

Pulmonary inflation and deflation (Fig. 6B)

During all the test period, an intrapulmonary pressure above 10 mm Hg cancels the electrical activity of the external intercostals. This same stimulation causes a maintained tonic activity in the internal intercostals.

The effects are less marked when the pressure is slight, as Fig. 6B demonstrates where a small pulmonary inflation is used. Pulmonary deflation produces contrasting effects. The observed reflex changes are probably due to activation of the muscle spindles (Glebovskii 1965). The differences which exist between our results and those of Sant'Ambrogio and Widdicombe (1965) are probably due to the different intrapulmonary pressures used.

Inhibition of the diaphragm and interchondrals is observed at the beginning of either inflation or deflation.

External thoracic pressure (Fig. 6A)

This manoeuvre shows a difference between the interchondral response and that of the intercostals (Fig. 6A). As before, the intercostals present a maintained tonic activity during the entire stimulatory period. The opposition between the internal intercostals is less clear than formerly because of the probable activation of a number of cutaneous afferents. The interchondrals and diaphragm are inhibited only at the beginning of the stimulation.

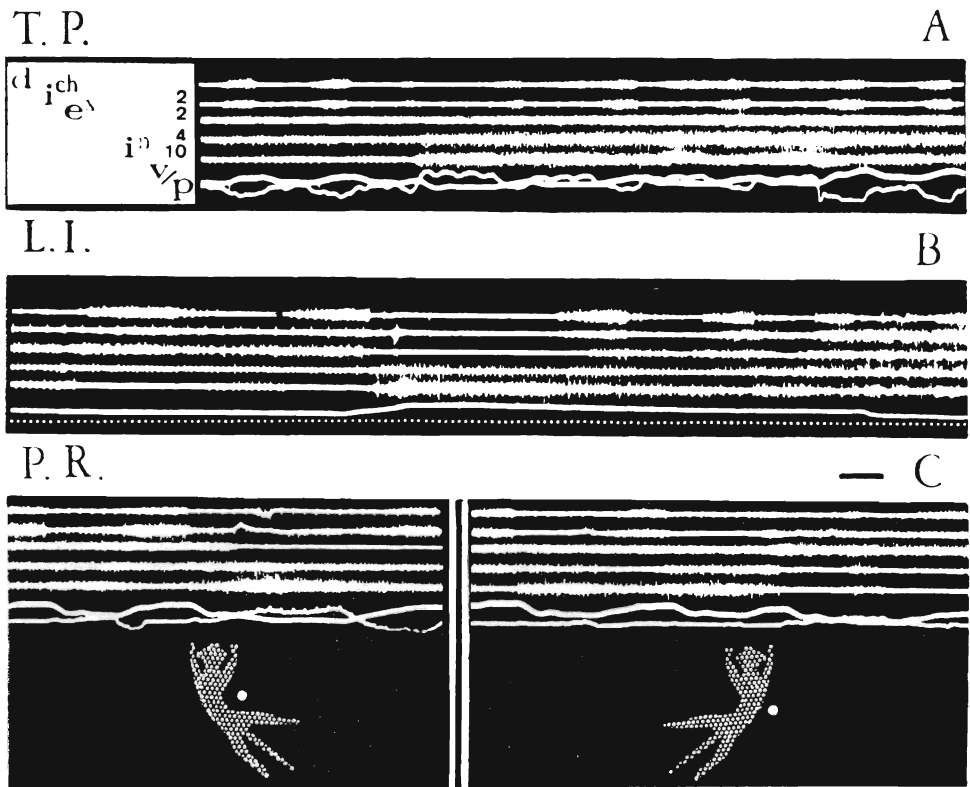


Fig. 6. Reflex activation of the respiratory muscles in the decerebrate vagotomized cat. The recordings were obtained from the same muscles in the three records (A, B, and C). *d*, diaphragm; *ich*, interchondral; *ex*, external intercostal; *in*, internal intercostal; *v*, volume; *p*, oesophageal pressure. In A the effect of thoracic pressure (T. P.); B, the effects of lung inflation (L. I.); C, postural reflex (P. R.) produced by passive incurving of the thorax. The white point marks the side of the cat studied. Note at the beginning of each stimulation the inhibition of the diaphragmatic and interchondral activity. During the stimulation note in B and C the antagonistic effects in the external internal intercostals. Time scale, 1 sec.

Passive inward displacement "incurving" of the thorax (Fig. 6C and 7)

Passive incurving of the thorax, at the level of the ipsilateral muscles, causes an inhibition of external intercostal activity. In the same conditions, one notices a reinforcement of the internal intercostal activity. Inverse effects are produced by lateral incurving of the thorax on the opposite side. One may also find opposite effects in the ipsilateral and contralateral muscles of the same group. Phasic and inspiratory activity and

especially that the interchondrals and diaphragm are modified only in the initial phase of postural change. If this is done rapidly inhibition is observed. All these postural manifestations are sometimes difficult to witness since in every reactive animal there is diffusion of the reflexes. This may explain the divergences which may exist between our results and those of Corda, Euler and Lennerstrand (1965). All these reflexes are cancelled by bilateral dorsal root section if enough roots are cut (Sears 1963).

The reflexes persist in the intercostals after spinal section at C₇. Inhibition of the diaphragm and of the interchondrals is not manifested in these experiments. These different results show the importance of the segmental and polysegmental circuits in the activation of the external and internal intercostals while these same circuits do not seem to




Fig. 7. Postural reflex. Three sequences are represented. In each one of them the same muscles are used for recording. The white point indicates the muscles of the right side: interchondral (1) and external intercostals (2) from the 3rd space. The white arrow indicates the muscles of the left side (3rd space): interchondral (3) and external intercostal (4). The uppermost record represents the control. Note in A and B the antagonistic effects produced by the lateral incurving of the thorax in the ipsilateral muscles. Note also the absence of effects on phasic inspiratory activity present in the different muscles. Time scale, 1 sec.

play a very important part in control of the diaphragm and interchondrals.

In these different reflexes, the inspiratory inhibition only shows itself at the first inspiratory discharge. It can be related to influences arising from rapidly adapting receptors. This inhibition disappears when one makes a hemisection of the spinal cord together with complete section of the contralateral dorsal roots. Given that there is a decussation of the descending respiratory fibres at the level of each segment (Duron 1970), it is probable that this inhibition is brought about in the respiratory centre. The long ascending sensory pathways are probably involved.

Total postural movement of the animal (Fig. 8)

It is possible to tilt the animal in the sagittal plane with its head downwards using a mobile experimental table. This manoeuvre is interesting because it stimulates both ventilation and postural function (Fig. 8). In these cases, the tonic external intercostal activity is rein-

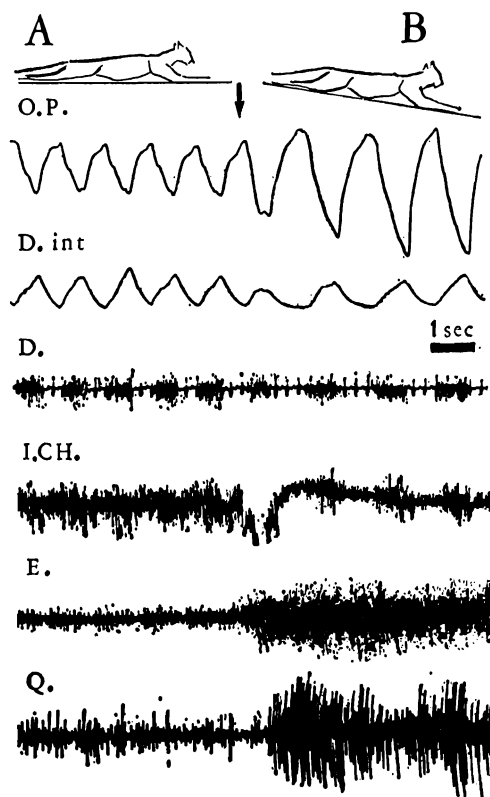


Fig. 8. Postural reflex. O. P., oesophageal pressure; D. int., integrated diaphragmatic activity; D., diaphragm; I. CH., interchondral; E., external intercostal; Q., quadriceps. In B, the cat was tilted downwards. The external intercostal muscles react in the same way as the quadriceps. The tonic activity of the interchondrals leaves room for a reinforcement of inspiratory activity.

forced in the same fashion as that of the paw extensors. The tonic interchondral activity, when it exists, is inhibited and allows an increase in inspiratory activity. These results confirm the postural origin of the various tonic activities and show that the interchondral muscles are most readily involved in ventilation while the external intercostals take part in postural function to a greater extent. The diaphragm is not involved in these postural changes.

The effect of pyramidal stimulation on the spontaneous electrical activity of the intercostal muscles (Fig. 9)

Andersen and Sears (1970) have recently studied the effects of stimulation of the medullary "respiratory centre" on the intercostal motoneurons. It was the aim of the present study to investigate non-specific influences on the same muscles, and this was achieved by stimulation of the pyramidal tract.

Several histological and electrophysiological studies have shown that the corticofugal projections have collaterals which go to the reticular formation of the brain stem. The pyramidal tract is not an exception to this (Kuypers 1958, Scheibel and Scheibel 1958, Szentagothai and Ratkovits 1958).

We limited ourselves to studying the effects of bulbar pyramidal stimulation on the electrical activity of the ventilatory muscles. In order to eliminate as much as possible the activation of the subcortical circuit and the reticulo-cortico-reticular loop we did this research on the decerebrate, unanaesthetized cat. Despite this, antidromic or orthodromic activation of the pyramidal tract collaterals is possible. This prevents one from interpreting the results in terms of exclusive pyramidal control of the muscles examined. The essential result is that we generally obtain opposite effects in the principal inspiratory muscles (diaphragm and interchondrals) from those in the external intercostals. Stimulation of the interior part of the pyramidal tract provokes a simultaneous activation of the paw muscles and of the external intercostals while it inhibits or has no action on diaphragmatic and interchondral activity.

In these conditions, the corresponding internal intercostal activity, when, it exists, is inhibited. Reciprocal innervation is perhaps activated. Stimulation of the external part of the pyramidal tract activates preferably the interchondral muscles and the diaphragm. The external intercostals may also be activated. These results may suggest that there is a double motor control of pyramidal origin (one being the internal part of the pyramid involved in postural control, the other being the external part of the pyramid influencing ventilation).

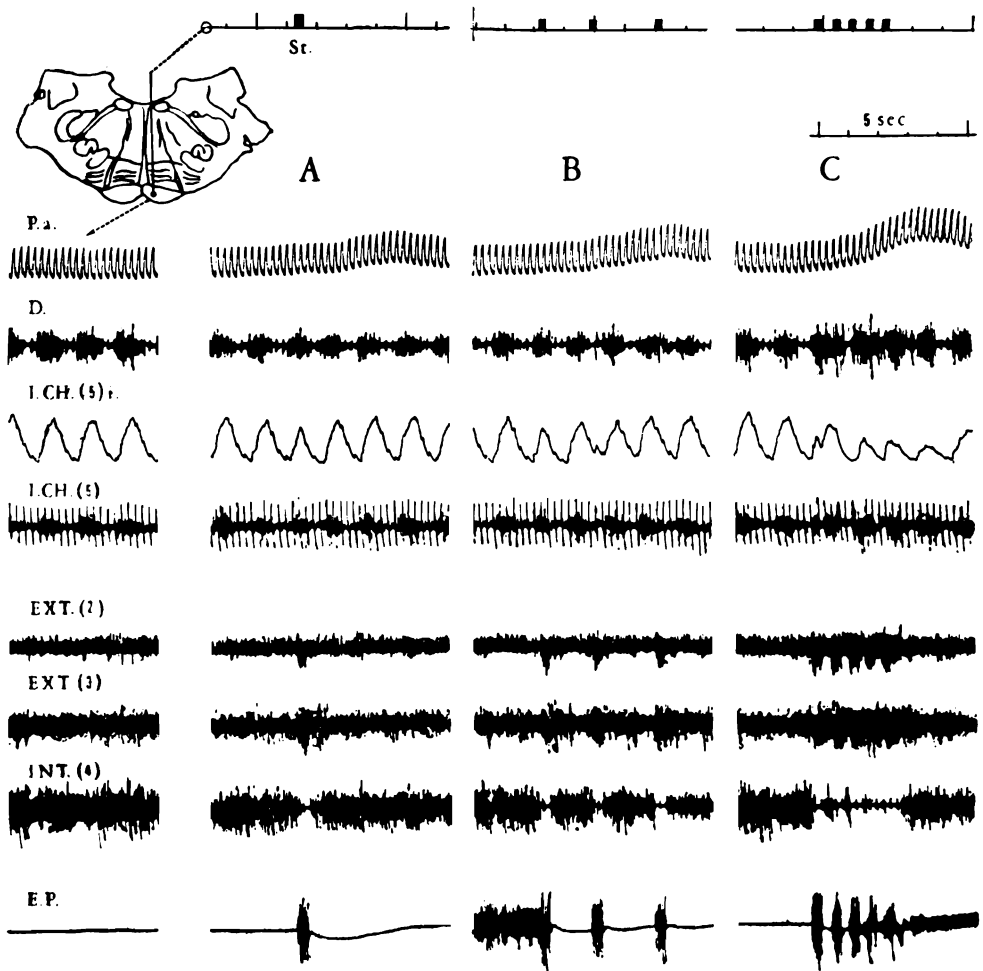


Fig. 9. Stimulation of the interior part of the pyramidal tract in the decerebrate cat. In each of the four sequences are represented from above-downwards. P.a., arterial pressure; D., diaphragm; I. CH. (5), integrated electrical activity of the 5th interchondral; Ext. (2) and (3), external intercostals of 2nd and 3rd spaces; Int. (4), 4th internal intercostal; E. P., posterior extensor. Stimulation: volleys of 0-1 sec duration with rectangular shocks of 50 μ sec, 7 v, 300 Hz. In A, B and C there is during each stimulation activation of the external intercostals accompanied by a clear inhibition of the internal intercostals. In the diaphragm and interchondrals there is only an inconstant, slight inhibition.

THE UNRESTRAINED ANIMAL WITH CHRONICALLY IMPLANTED ELECTRODES

We made this study in order to verify the differences observed in the comportment of the external intercostals and that of the diaphragm and

interchondral group during the acute experiments. We also correlated the electrical activity of the various muscles with the EEG during sleep.

A phasic inspiratory electrical activity characterises the electromyogram of the diaphragm and interchondrals in the reposed awake animal. An expiratory activity is easily recorded from the triangularis sterni. The external and internal intercostals present a tonic activity. The latter is feeble or absent in the seated animal. It is very clear in the crouching cat or in the cat lying on its side.

In the moving cat, the diaphragm and interchondrals always have a predominant inspiratory activity. The external and internal intercostals have most frequently a postural activity. This may be tonic (Fig. 10). Sometimes, it is phasic when the movement is repeated, but it has no respiratory rhythm. However, in certain instances, when the

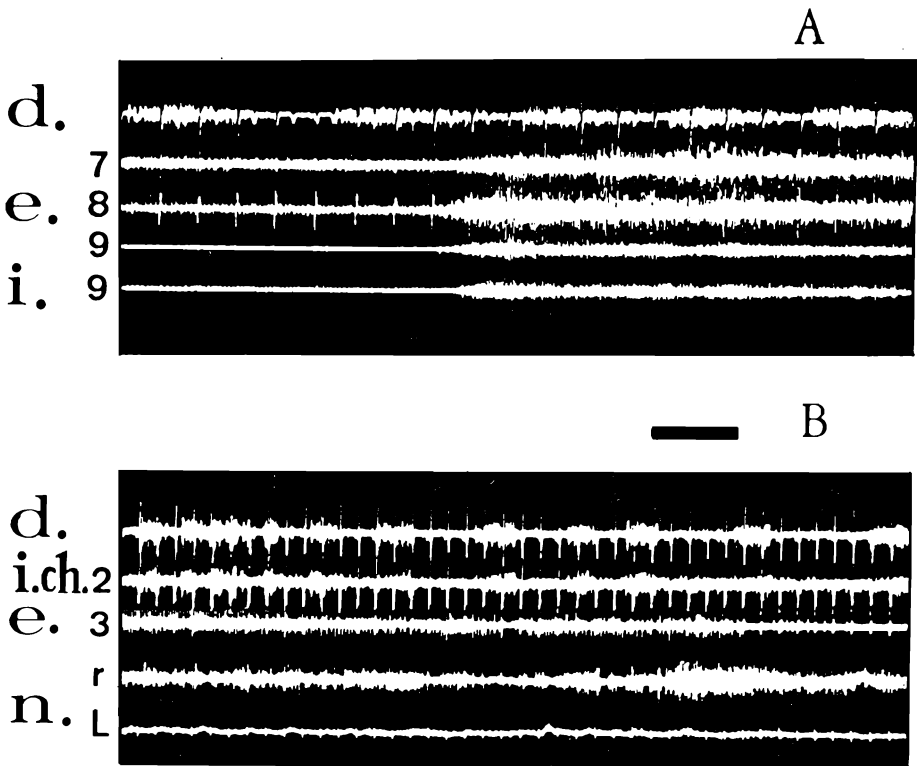


Fig. 10. Unrestrained cat with chronically implanted electrodes. The recordings A and B were obtained from two different animals. d., diaphragm; e., external intercostal; i., internal intercostal; i.ch., interchondral; nr and nL, neck muscles of right and left sides. Note the postural intercostal activity when the animal moves. Time scale, 1 sec.

animal shows a polypnoea (anxiousness, effort, purring), these muscles may show respiratory activity. Contrary to what is observed in acute experiments, the external intercostals of the inferior spaces are active. As for the others this activity, most commonly postural, may show a respiratory rhythm.

During paradoxical sleep, unlike the inspiratory muscles whose activity is unmodified, the external intercostal activity disappears after that of the neck muscles (Duron et al. 1966, Duron 1966, 1970, Islas-Marroquin 1966).

THE RELATIVE DENSITY OF MUSCLE SPINDLES IN THE INTERCOSTAL MUSCLES

In 1902, Hüber showed that the intercostals of the superior spaces are richer in muscle spindles than are the inferior ones. But this author did not define whether this applied to internal or external intercostals. On the other hand, we know from the anatomical investigations of Dogiel (1902) and Winkler and Delaloye (1957) and from electrophysiological studies of Cuenod (1961), Glebovskii (1962) and Corda, Euler and Lennerstrand (1965), that the diaphragm is very poor in muscle spindles. Therefore, it seemed essential to complete this information by a systematic study of the intercostal and interchondral muscles of the various spaces. These histological studies are long and imprecise because it is difficult to appreciate exactly the dry weight of the samples. This difficulty may involve some error in the evaluation of the exact number of spindles per unit weight of muscle. However, the differences are such that it is possible to affirm that the concentration of spindles in the superior spaces is higher than that in the inferior ones.

At the level of the third and fourth intercostal spaces the external intercostal contains an average of 100 spindles per gram of dry weight whereas the internal intercostal contains an average of only 50. The values for the same muscles of the 8th space are, on the average, 60 and 30 respectively. These results show also that the external intercostals are richer in spindles than the internal intercostals. The latter are in their turn richer than the interchondral muscles. In fact, we found 22 spindles per gram of dry weight in the 2nd interchondral muscle (Fig. 11). There is certainly a difference in the absolute value from cat to cat, but the division between the different groups of muscles seems to be constant enough. The study of myelinated fibres of the corresponding nerves agrees with these results (Sears 1964*ab*, Duron 1968*c*). Thus, the muscles which are richest in spindles are those which are involved least in ventilation but have important postural functions.

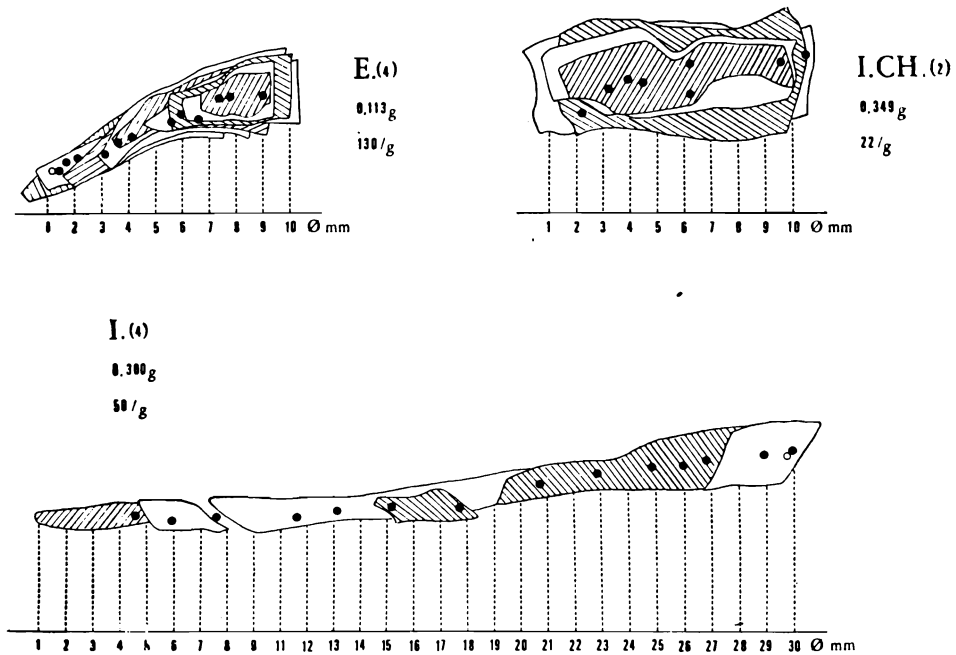


Fig. 11. Location of muscle spindles in three different respiratory muscles. E. (4), external intercostal (4th space); I. CH. (2), interchondral (2nd space); I. (4), internal intercostal (4th space). The black points mark the spindles. The open circles mark the tandem spindles. Note the great difference in the relative spindle density in the three muscles. 130 spindles per gram (E). 50 spindles per gram (I). 22 spindles per gram (ICH).

DISCUSSION

The first topic to discuss is the exact origin of the recorded electrical activities. In fact, it is all too easy to record activity from neighbouring muscles when one places an electrode in such slight muscles as those of the intercostal spaces. Thus we prudently verified the exact position of the electrode in the muscle studied at the end of each experiment. After placing plastic slips between the various muscles planes we were able to establish a control in certain cases and the results agreed with those of our experiments.

PHASIC ACTIVITY WITH RESPIRATORY RHYTHM

Our results on the phasic inspiratory and expiratory activities of the different muscles agree completely with those of Bronk and Ferguson (1934) from the cat, of Sant'Ambrogio and Widdicombe (1965) from the

rabbit and also of Koepke et al. (1955, 1958) and Taylor (1960) from man. Therefore there does not seem to be any noteworthy difference between the various mammalian species. The principal inspiratory muscles are thus the diaphragm and the interchondrals. All the same the superior, external intercostals may present a typical inspiratory activity. This is however rare but may be observed in the anaesthetized and exceptionally in the decerebrate cat. This seems to confirm the results obtained by Eccles, Sears and Shearly (1962), Sears (1963) and Andersen and Sears (1970). The last assert that the intercostal motoneurons are under the influence of the respiratory centre. This influence seems to be less pronounced than at the level of the diaphragmatic and interchondral motoneurons. In particular conditions (during effort) an inspiratory activity was observed in the inferior external intercostals of the unrestrained cat with chronically implanted electrodes. Remembering that the latter muscles are nearly always inactive in the decerebrate animal, one may question whether they are profoundly influenced by the respiratory centre and whether their activation does not necessitate the intervention of corticofugal projections.

Phasic expiratory activity is especially marked in the *triangularis sterni* and in the abdominal muscles (especially in the *transversus abdominalis*) in agreement with the findings of Bishop (1967). The inferior, internal intercostals may also present an expiratory activity.

THE INFLUENCE OF THE PARIETAL THORACIC AFFERENT NERVES ON THE PHASIC ACTIVITY

Our histological results show that the muscles with the least concentration of muscle spindles are those which show the clearest phasic, ventilatory activity. This is especially true for the diaphragm and interchondrals. Like Decima and Euler (1969), we were unable to show that the diaphragm participates in postural function. In the same way, interchondral electrical activity was not influenced to any extent by the different stimulations (such as a passive movement and pulmonary inflation and deflation) which we used. In the same experimental conditions, we observed in exceptional cases analogous results in the inspiratory activity of the external intercostals since a superimposed tonic activity did not mask the effect. Furthermore, since neither decerebration nor dorsal root section modify the phasic, inspiratory activity of the diaphragm and interchondrals, it seems that the few afferent nerves that arise from these muscles do not play an important role in their activation. Moreover these afferent fibres do not seem to influence the respiratory rhythm during eupnoea. However, they do play a significant role in the activation of the external intercostals. It might therefore be consid-

ered that the projection from the respiratory centre to the motoneurons of these muscles is less important than for the diaphragm and interchondral muscles. In the same way expiratory internal intercostal activity seems to be very dependent on the parietal thoracic afferents and especially those of muscular origin. This suggests some difference in the central organization of the inspiratory and expiratory systems. The output from the expiratory centre does not have the same importance as that from the inspiratory centre in this respect.

TONIC ACTIVITY WITHOUT RESPIRATORY RHYTHM

The tonic intercostal activity observed either spontaneously or when elicited by the stretch reflex is never accompanied by tonic respiratory seizures analogous to those observed by Monnier (1938). This tonic activity is found to the greatest extent in the muscles which have the highest concentration of muscle spindles. This is exactly oppositely to the previous situation. Thus one observes them mainly in the superior external intercostal muscles. Our electrophysiological findings confirm the important role which the gamma loop plays in the activation of these muscles (Andersen and Sears 1970). Indeed, the external intercostal activity is greatly modified by decerebration and by dorsal root section, and the stretch reflexes (according to Glebovskii 1965) are very marked in these muscles. The external intercostal muscles readily participate in thermal shivering and, furthermore, the gamma loop has been shown to play an important role in this mechanism (Euler and Söderberg 1957, Simon 1968).

Corde, Euler and Lennerstrand (1965) have shown that the intercostal fusimotor fibres can be divided into two functionally different groups comprising: (i) the specifically respiratory or "rhythmic" gamma neurons which discharge in synchrony with the respiratory alpha motoneurons; and (ii) the tonically firing ones whose discharge can be influenced by impulses from the skin over the thorax and by postural reflexes. Our results lead us to believe that in the external intercostals it is the second group which is most numerously represented. Thus the difference in the concentration and in the quality of spindles would be sufficient to explain the differences in the inspiratory muscle behaviour. These could also be a difference in the density of nonspecific projections to diverse motoneurons. Thus the intercostal muscles might be subjected to greater pyramidal control than either the diaphragm or the interchondrals. These latter are essentially influenced by the respiratory centre and seem to be the fundamental respiratory muscles.

The internal intercostal muscles which have fewer spindles than the external intercostal muscles are less involved in the rigidity induced by

decerebration. Probably, according to Sears (1964*ab*), this apparent inactivity could be related to the mechanism of reciprocal inhibition. From this point of view, there is some analogy with the flexors of limbs. The observed difference in behaviour of the so-called classical inspiratory muscles does not implicate any structural difference in the central organization of their motor control but rather implies a difference in the relative density of central and peripheral projections influencing motoneuron activity. Our results have prompted us to consider the external and internal intercostals as particular postural muscles. These muscles which, depending on the circumstances, may be involved in ventilation or in posture, cannot be considered as having only an accessory role. The role in postural function of the thorax can be considered from two view points: one the thoracic movements and the other the thoracic tone. In the first, the external and internal intercostals have essentially an influence on "pulmonary distribution" and they may participate in voluntary inspiratory movements; in the second, they may have an influence on the functional residual capacity of lungs. Postural and ventilatory functions are intricate at the level of the thorax.

REFERENCES

- ANDERSEN, P. and SEARS, T. A. 1970. Medullary activation of intercostal fusimotor and alpha motoneurons. *J. Physiol. (Lond.)* 209: 739-755.
- BISHOP, B. 1967. Diaphragm and abdominal muscle responses to elevated airway pressures in the cat. *J. Appl. Physiol.* 23: 959-965.
- BRONK, D. W. and FERGUSON, L. K. 1934. The nervous control of intercostal respiration. *Amer. J. Physiol.* 110: 700-707.
- CAMPBELL, E. J. M. 1952. An electromyographic study of the role of the abdominal muscles in breathing. *J. Physiol. (Lond.)* 117: 222-233.
- COMROE, J. M., FORSTER, E. R., DUBOIS, A. B., BRISCOE, A. W. and CARLSEN, E. 1967. *Physiologie de la respiration*. Masson éditeur, Paris. 263 p.
- CORDA, M., EULER, C. von, and LENNERSTRAND, G. 1965. Proprioceptive innervation of the diaphragm. *J. Physiol. (Lond.)* 178: 161-178.
- CRITCHLOW, C. and EULER, C. von 1963. Intercostal muscle spindle activity and its gamma motor control. *J. Physiol. (Lond.)* 184: 898-923.
- CROSFILL, M. L. and WIDDICOMBE, J. G. 1961. Physical characteristics of the chest and lungs and the work of breathing in different mammalian species. *J. Physiol. (Lond.)* 158: 1-14.
- CUENOD, M. 1961. Réflexes proprioceptifs du diaphragme chez le lapin. *Helv. Physiol. Pharmacol. Acta* 19: 360-372.
- DECIMA, E. and EULER, C. von 1969. Intercostal and cerebellar influences on efferent phrenic activity in the decerebrate cat. *Acta Physiol. Scand.* 76: 148-158.
- DELHEZ, L., PETIT, J. M. and MILIC EMILI, G. 1959. Influence des muscles expirateurs dans la limitation de l'inspiration (étude électromyographique chez l'homme). *Rev. Fr. Et. Clin. Biol.* 4: 815-818.

- DOGIEL, A. S. 1902. Nervenendigungen im Bauchfell in den sehnen, den Muskelspindeln deln und dem centrum tendineum des Diaphragmas beim Menschen und bei Säugethieren. *Arch. Wikr. Anat.* 59: 1-31.
- DURON, B. 1966. Etude comparative des muscles thoraciques du chat dans la respiration, la posture et le frisson thermique. *J. Physiol. (Paris)* 58: 514.
- DURON, B. 1968a. Influence comparée de l'anesthésie et de la section des racines dorsales sur l'électromyogramme des muscles respiratoires du chat décérébré. *J. Physiol. (Paris)* 60 (Suppl. 2): 436-437.
- DURON, B. 1968b. Activation réflexe des muscles respiratoires du chat par des afférences pariétales thoraciques. *Proc. XXIV Int. Congr. U. Physiol. Sci. (Washington)* 7: 121.
- DURON, B. 1968c. Contribution à l'étude des muscles respiratoires. Ph. D. Thesis. Faculté des Sciences, Marseille.
- DURON, B. 1970. Le "crossed phrenic phenomenon". *J. Physiol. (Paris)* 62 (Suppl. 1): 149.
- DURON, B. and CAILLOL, M. C. 1971a. Activité électrique des muscles intercostaux au cours du frisson thermique chez le chat anesthésié. *J. Physiol. (Paris)* 63: 523-538.
- DURON, B. and CAILLOL, M. C. 1971b. Volées afférentes dans le nerf phrénique intact au cours de la respiration spontanée chez le chat. *J. Physiol. (Paris)* (in press).
- DURON, B. and CONDAMIN, M. 1968. Etude topographique des plaques motrices au niveau des muscles respiratoires du chat. *Z. Zellforsch.* 85: 315-321.
- DURON, B. and CONDAMIN, M. 1969. L'innervation intercostale accessoire du diaphragme chez le chat. *C. R. Soc. Biol. (Paris)* 163: 1859-1864.
- DURON, B. and REGIS, H. 1967. Etude polygraphique des effets de l'éther, du Nembutal et du Vallium sur l'activité électrique des muscles respiratoires chez le chat. *Electro-Diagnostic Therap.* 1: 1-29.
- DURON, B., TASSINARI, C. and GASTAUT, H. 1966. Etude spirométrique et électrophysiologique de la respiration au cours du sommeil contrôlé par l'E.E.G. chez l'homme normal. *Rev. Neurol.* 115: 562-574.
- ECCLES, R. M., SEARS, T. A. and SHEARLY, C. N. 1962. Intracellular recording from respiratory motoneurons of the thoracic spinal cord. *Nature* 193: 844-846.
- EULER, C. von 1961. Physiology and pharmacology of temperature regulation. *Pharmacol. Rev.* 3: 361-398.
- EULER, C. von and SODERBERG, U. 1957. The influence of hypothalamic thermoreceptive structures on the electroencephalogram and gamma motor activity. *Electroenceph. Clin. Neurophysiol.* 9: 391-408.
- GLEBOVSKIĬ, V. D. 1962. Stretch receptors of the diaphragm (in Russian). *Fiziol. Zh. SSSR* 48: 545-555.
- GLEBOVSKIĬ, V. D. 1965. Stretch reflexes of intercostal muscles (in Russian). *Fiziol. Zh. SSSR* 51: 1420.
- HAMBERGER, G. E. 1748. *Dissertatio de respirationis mechanismo et usu genuino.* Jena.
- HEMINGWAY, A. 1963. Shivering. *Physiol. Rev.* 43: 397-422.
- HÜBER, C. 1902. Neuromuscular spindles in the intercostal muscles of the cat. *Amer. J. Anat.* 1: 520-521.
- ISLAS-MARROQUIN, J. 1966. L'activité des muscles respiratoires pendant les différentes phases du sommeil physiologique chez le chat. *Arch. Sci. Physiol.* 20: 219-231.

- JONES, D. S., BEARGIE, R. D. and PAULY, J. E. 1953. An electromyographic study of some muscles of costal respiration in man. *Anat. Rec.* 117: 17-24.
- KOEPKE, G. H., MURPHY, A. J., RAE, W. J. and DICKINSON, D. G. 1955. An electromyographic study of some of the muscles used in respiration. *Arch. Physiol. Med.* 36: 217-222.
- KOEPKE, G. H., SMITH, E. M., MURPHY, A. J. and DICKINSON, D. G. 1958. Sequency of the action of the diaphragm and intercostal muscles during respiration. *Arch. Physiol. Med.* 39: 426-430.
- KUYPERS, H. G. J. M. 1958. An anatomical analysis of corticobulbar connexions to the pons and lower brain stem of the cat. *J. Anat. (Lond.)* 92: 198-218.
- MAGNUS, R. 1924. *Koperstellung*. Vol. 1. J. Springer Verlag, Berlin. 740 p.
- MASSION, J., MEULDERS, M. and COLLE, J. 1960. Fonction posturale des muscles respiratoires. *Arch. Int. Physiol.* 68: 314-316.
- MONNIER, M. 1938. Physiologie des formations réticulées. II. Respiration. Effets de l'excitation faradique du bulbe chez le chat. *Rev. Neurol.* 69: 517-523.
- PATON, W. D. M. and SPEDEN, R. N. 1965. Uptake of anaesthetics and action on the central nervous system. *Brit. Med. Bull.* 21: 44-47.
- RAMOS, J. G. 1959. On the integration of respiratory movements. *Acta Physiol. Lat.-Amer.* 9: 246-256.
- RAMOS, J. G. and MENDOZA, E. 1959. On the integration of respiratory movements. II. The integration at spinal level. *Acta Physiol. Lat.-Amer.* 9: 257-266.
- RICHTER, C. 1893. Le frisson comme appareil de régulation thermique. *Arch. Biol. (Paris)* 5: 312-326.
- ROBSON, J. G., HOUSELEY, M. A. and SOLIS-QUIROGA, O. H. 1963. The mechanism of respiratory arest with sodium pentobarbital and sodium thio-pental. *Ann. N. Y. Acad. Sci.* 109: 494-504.
- ROSSIER, P. H., NIEPORENT, M. J. W., PIDBERGER, M. and KÄLIN, R. 1956. Electromyographic studies on respiratory muscle function in normal volunteers. *Z. Ges. Exp. Med.* 127: 39-52.
- SANT'AMBROGIO, G. and WIDDICOMBE, J. G. 1965. Respiratory reflexes acting on the diaphragm and inspiratory intercostal muscles of the rabbit. *J. Physiol. (Lond.)* 180: 766-779.
- SEARS, T. A. 1963. Activity of fusimotor fibres innervating muscle spindles in the intercostal muscles of the cat. *Nature* 197: 1013-1014.
- SEARS, T. A. 1964a. The fibre calibre spectra of sensory and motor fibres in the intercostal nerves of the cat. *J. Physiol. (Lond.)* 172: 150-161.
- SEARS, T. A. 1964b. The slow potential of thoracic respiratory motoneurons and their relation to breathing. *J. Physiol. (Lond.)* 175: 404-424.
- SCHEIBEL, M. E. and SCHEIBEL, A. B. 1958. Structural substrates for integrative patterns in the brain stem reticular core. In H. H. Jasper, L. D. Proctor, R. S. Knighton, W. C. Noshay and R. T. Costello (ed.), *Reticular formation of the brain*. Henry Ford Hospital Int. Symp. Little, Brown and Co., Boston, p. 31-68.
- SEVERINGHAUS, J. W. and LARSON, J. R. 1964. Respiration in anesthesia. In W. O. Fenn and H. Rahn (ed.), *Handbook of physiology*. Sect 3, Respiration, Vol. II. Amer. Physiol. Soc., Washington, p. 1219-1264.
- SIMON, I. 1968. Spinal mechanisms of temperature regulation. *Proc. XXIV Int. Congr. U. Physiol. Sci. (Washington)* 6: 289-290.
- SZENTAGOTHAI, J. and RATKOVITS, K. 1958. Der hirnnervanteil der pyramiden-

- bahn und der pramotorische apparat motorischer hirnnervkerne. Arch. Psychiat. Nervenkr. 197: 335-354.
- TAYLOR, A. 1960. The contribution of the intercostal muscles to the effort of respiration in man. J. Physiol. (Lond.) 151: 390-402.
- TOKIZANE, T., KAWAMATA, K. and OKIZANE, H. 1952. Electromyographic studies on the human respiratory muscles. Jap. J. Physiol. 2: 232-247.
- WINCKLER, G. and DELALOYE, B. 1957. A propos de la présence de fuseaux neuromusculaires dans le diaphragme humain. Acta Anat. 29: 114-116.
- WRIGHT, S. 1961. Applied physiology. Vol. 1. Oxford Univ. Press, London. 555 p.

B. DURON, Laboratoire de Neurophysiologie, Faculté de Médecine, 12 rue Frédéric Petit, 80 Amiens, France.